

Date: 24.06.2023; 1402/04/03

Patient's Name: T.H

Responsible Physician: Dr. Mohagheghi

**Patient presentation:** A 38 year-old woman with positive family history in her

**Mammography:** Micro Calcification

**Sonography:** Axillary lymph node (ALN) is suspicious.

**CNB:**

Breast: ADH, Fibrocystic change

ALN: IDC, Luminal

**Question:**

What is the treatment plan?

**Recommended plan:**

- Surgery

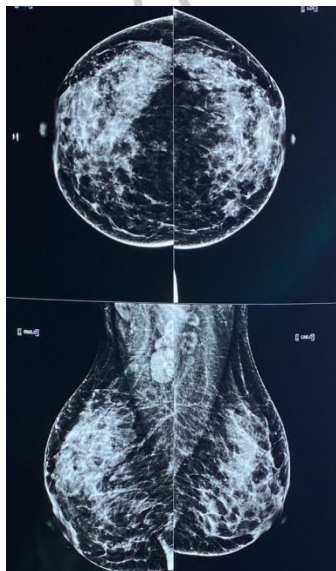


Figure1: Mammography

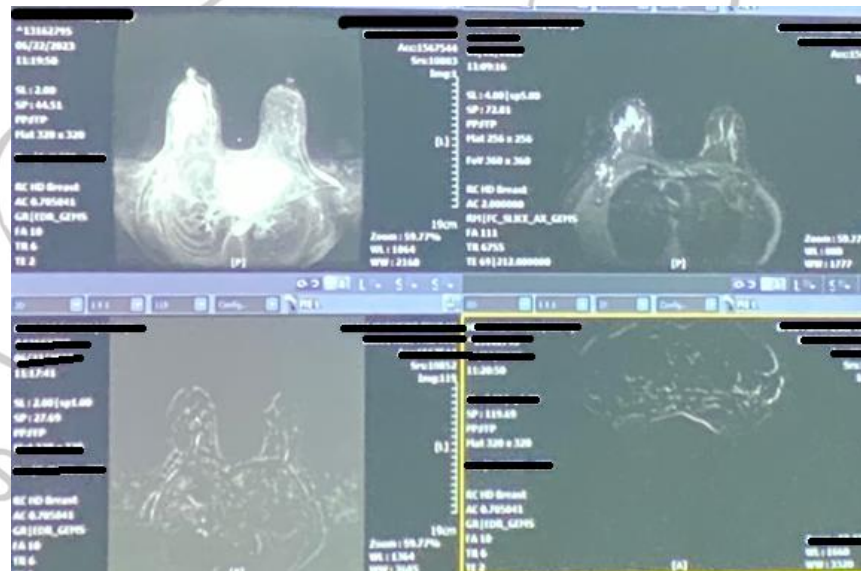

Figure 2: Breast MRI