

Date: 24.06.2023; 1402/04/03

Patient's Name: T.Z

Responsible Physician: Dr.Motamedi

Patient presentation: A 75 year-old woman with right medial breast ulcerated mass, and left vocal fold immobilization. She is under Letrozole treatment. Ulceration is improved.

CT scan: Thyroid Nodule

CNB: IDC, Luminal B, Ki67: 20%

PET scan: No metastases

Question:

What is the treatment plan?

Recommended plan:

1. Breast MRI
2. Thyroid FNAB
3. Breast surgery

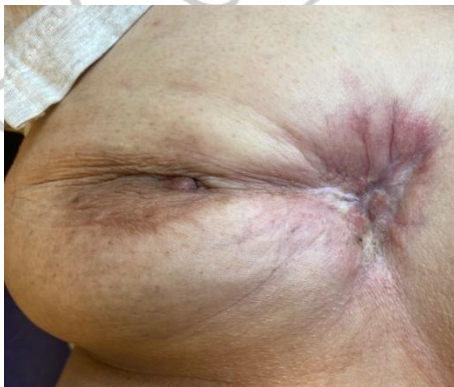

Figure 1: Ulcerative Breast Lesion Post history

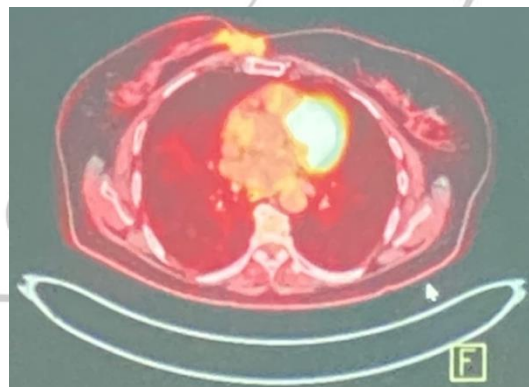


Figure 2: PET scan, only shows sternum Involvement