

Date: 10.06.2023; 1402/03/20

Patient's Name: Z.S

Responsible Physician: Dr.Esphandbod

Patient presentation: A woman with right Locally Advanced Breast Cancer (LABC); she underwent Modified radical mastectomy Post Neoadjuvant chemotherapy.

CNB: ER: negative, PR: negative, HER2: positive.

PET scan: normal

MRI: Multiple Hemangiomas in liver, 2 suspicious metastases in liver, and 1 liver lesion is proven to be metastases.

Question:

What is the plan for liver metastases?

Recommended plan:

Liver segmentectomy (segments V and VII).

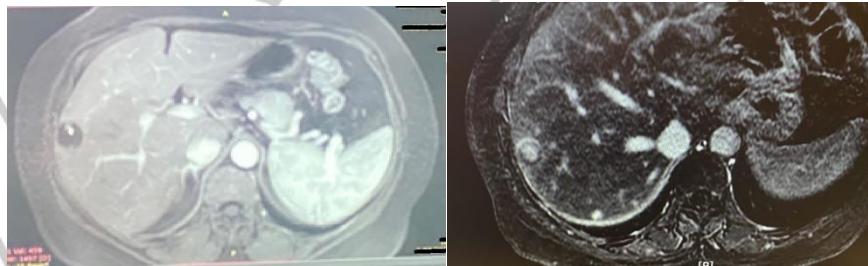


Figure 1, 2: Liver MRI, Metastases

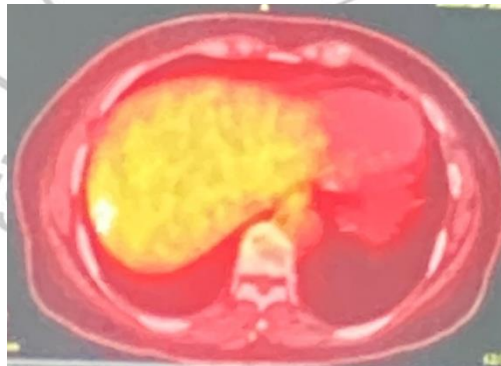


Figure 3: PET scan, Liver Metastases