

Date: 10.06.2023; 1402/03/20

Patient's Name: T

Responsible Physician: Dr.Esphandbod

Patient presentation: A 40 year-old woman with triple negative left breast cancer. Post NAC Surgery (Mastectomy) is done for her, now she has a mass in right breast.

Mammography: Right breast mass

Sonography: normal

Genetic Test: negative

Question:

How right breast mass should be managed?

Recommended plan:

Right target sonography recommended if it is negative, stereotactic biopsy under mammography guidance will be recommended.

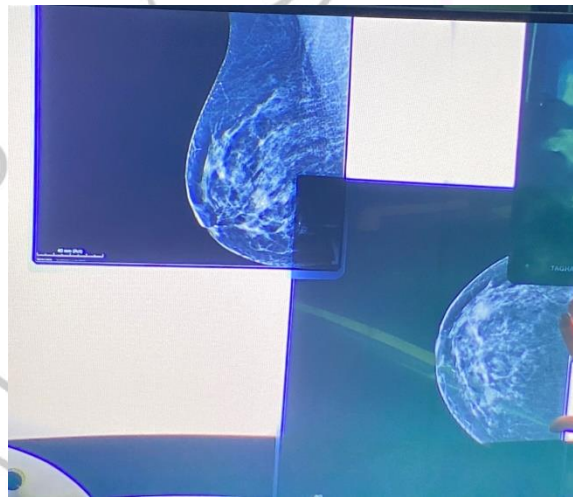


Figure1: Mammography, asymmetry.