

Date: 27.05.2023; 1402/03/06

Patient's Name: N.A

Responsible Physician: Dr.Hashemi

Patient presentation: A 49 year-old woman with history of BCS from 7 years ago, she has loco-regional recurrence in her breast, HER-2: positive and she is under Tamoxifen and Herceptin Treatment. Now skin lesion appeared after Pertuzumab treatment.

Question:

What should be done about skin lesion?

Recommended plan:

Skin lesions show inflammation:

1. Biopsy of right breast Medial skin lesion
2. Palliative mastectomy

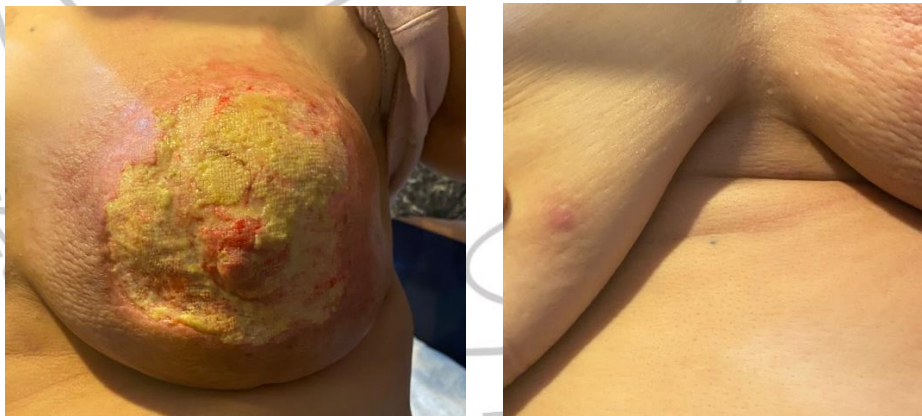


Figure 1, 2: Skin Lesions