

Date: 20.05.2023; 1402/02/30

Patient's Name: M.J

Responsible Physician: Dr.Motamedi

Patient presentation: A 74 year-old woman with right breast cancer local recurrence and she is under tamoxifen therapy.

IHC: ER: negative, PR: negative, HER-2: positive, Ki67: 30%.

Scan: Suspicious Bone Mets, Cardiomyopathy maybe Amiloidosis.

Echocardiography: Left ventricular ejection fraction (LVEF) <20%.

Question:

What is the treatment plan?

Recommended plan:

1. Local Excision w/o SLN
2. Cardiology reevaluation
3. Amyloidosis confirmation

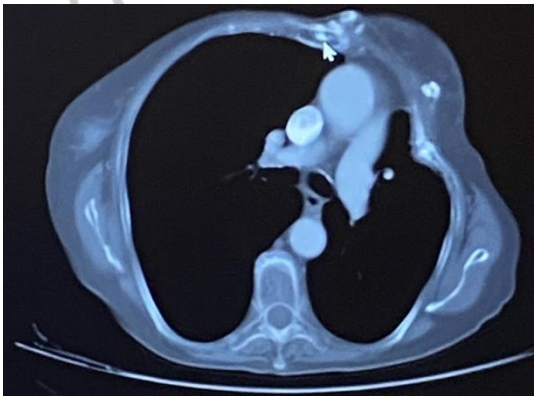


Figure1: Sternum Lesion

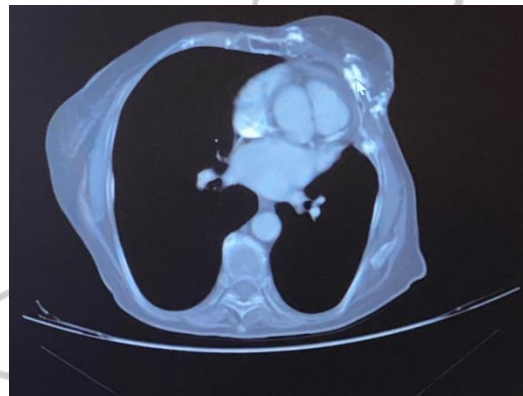

Figure2: Chest wall Lesion