

Date: 18.11.2023; 1402/08/27

Patient's Name: B.S

Responsible Physician: Dr.Tuge

Patient presentation: A 42 year-old woman who underwent left BCT and Radiotherapy and Herceptin intake 3 years ago.

CNB: IDC, ER: negative, PR: negative, HER-2: triple positive.

PET scan: Cervical supra clavicular and Axillary node, right Breast mass.

Biopsy: GATA: positive, ER: negative, PR: negative, HER-2: negative, Ki67: 40%.

Question:

What is the treatment plan?

Recommended plan:

- 1- Anti HER-2
- 2- Combination of Herceptin and Perjeta
- 3- Breast MRI

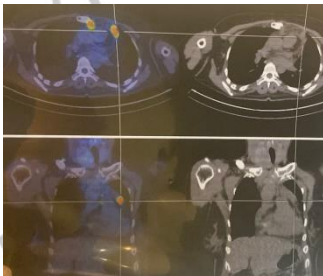


Figure1: PET scan.

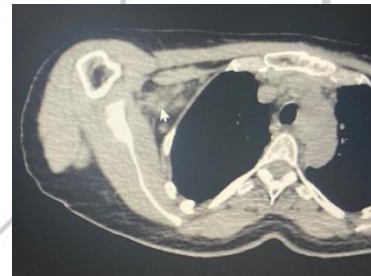
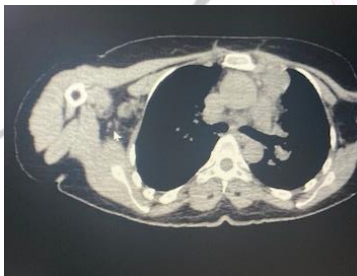
Figure 2, 3: CT scan.

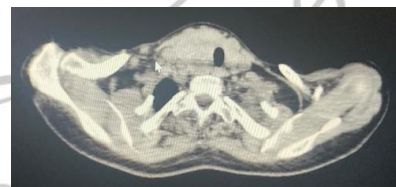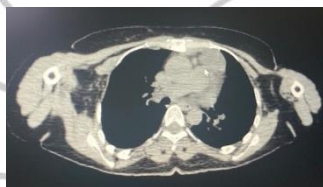

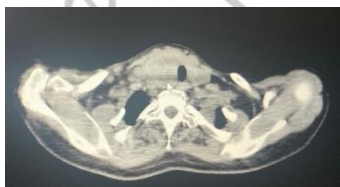
Figure 4, 5, and 6: CT scan.