

Date: 11.11.2023; 1402/08/20

Patient's Name: S.B

Responsible Physician: Dr.Esphandbod

Patient presentation: A 66 year-old woman who underwent MRM, Rdiotherapy and Aromasin intake in 1393. She had pelvic and Epigastric pain in1401.

PET scan: Metastasis in pelvic bone XRT.

Endoscopy: Pyloric mass.

Pathology: Adenocarcinoma, poorly different GATA: negative.

CT scan: Early gastric cancer.

Question:

What is the treatment plan for Gastric cancer?

Recommended plan:

- Like early gastric cancer, Endo-US then complete cancer workup.

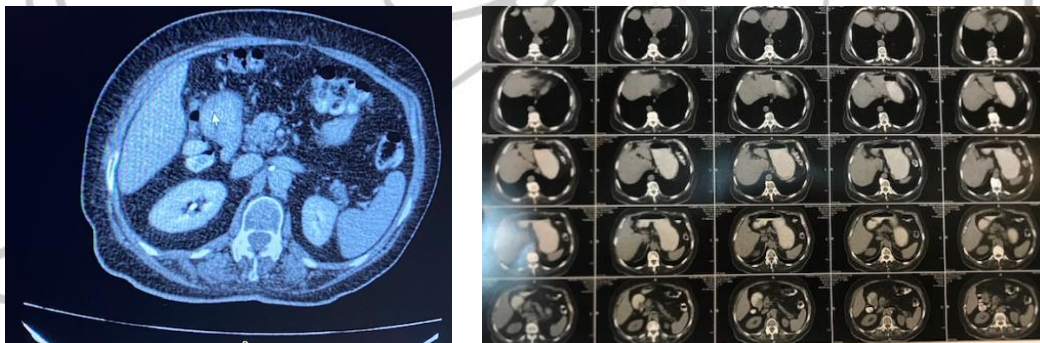


Figure 1, 2: CT scan.

Clinical Data:
A 65-year-old lady with history of breast cancer now presents with following findings in endoscopic evaluation:
Stomach: Cardia and fundus and body and antrum were normal, fungating medium tumor in pyloric
Specimen:
Pyloric mass
Macroscopic:
The specimen is received in formalin labeled as pyloric mass consists of multiple fragments of soft tissue measuring 1x0.4x0.2 cm SOS:M/1 E:100%
Microscopic:
IHC study results
-CK7: Positive in tumor cells
-Gata3: Negative in tumor cells
-ER: Negative in tumor cells
Diagnosis:
Pyloric mass, Endoscopic biopsy:
-Poorly-differentiated adenocarcinoma of primary origin according to IHC Study

Figure 3: IHC report.