

Date: 28.10.2023; 1402/08/06

Patient's Name: Z.E

Responsible Physician: Dr.Mohammadi

Patient presentation: A 40 year-old woman with history of Breast Reduction. 4 months later she underwent Post Neoadjuvant Chemotherapy, 4sessions of AC, and now she has taken 9 sessions of TC.

Mammography: Suspicious mass.

CNB: ER: negative, PR: negative, HER-2: negative, Ki67: 70%, Review of Ki67: 90%.

Question:

What is the treatment plan?

Recommended plan:

- 1- Surgery
- 2- Post operational Radiotherapy

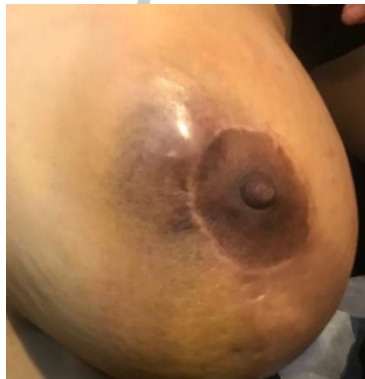

Figure 1: Breast mass.

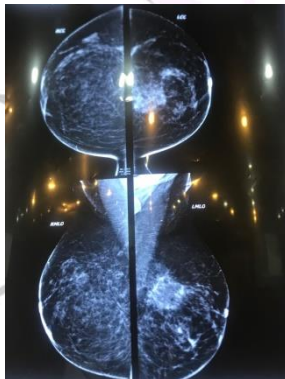


Figure 2: Mammography.

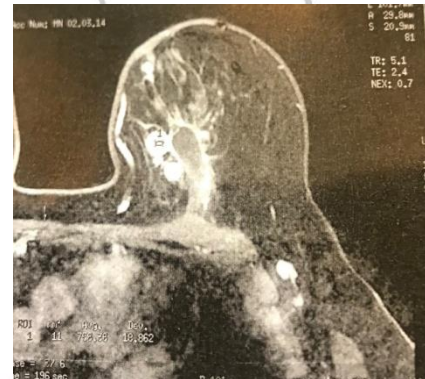

Figure 3: MRI of Breast.

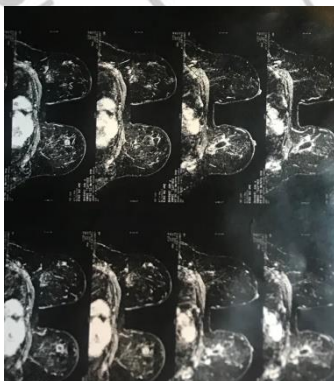

Figure 4: Lateral view of Breast MRI.

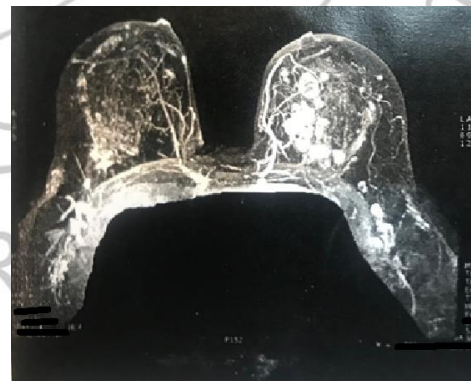


Figure 5: Sagittal view of Breast MRI.