

Date: 21.10.2023; 1402/07/29

Patient's Name: M.J

Responsible Physician: Dr.Esphandbod

Patient presentation: A 55 year-old woman known case of breast cancer.

Physical Exam: Palpable mass in right breast at 3 o'clock and normal Axilla.

Sonography: 31*22 mass at 3 o'clock and normal Axilla.

CT scan: Normal.

CNB: IDC, Grade: 2, ER: 90%, PR: 70%, Ki67: 20%, HER-2: double positive, FISH: positive.

Question:

What is the next plan?

Recommended plan:

- 1- Upfront surgery
- 2- Neoadjuvant chemotherapy

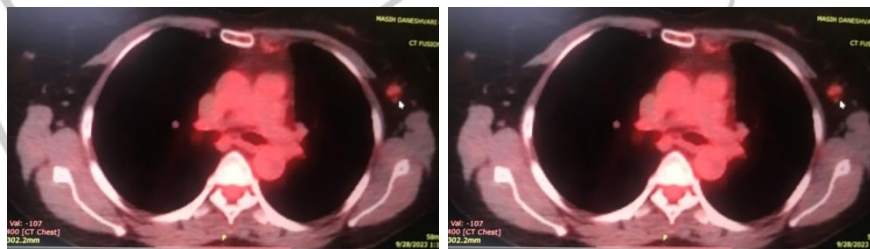


Figure 1, 2: CT scan shows lesion.

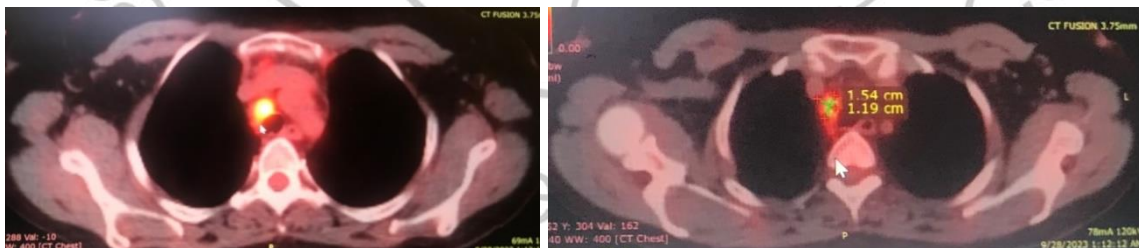


Figure 3, 4: CT scan shows supraclavicular node.