

Date: 21.10.2023; 1402/07/29

Patient's Name: F.M

Responsible Physician: Dr.Omranipour

Patient presentation: A 52 year-old woman with, she underwent Partial mastectomy and SLNB.

Mammography: Not palpable right Breast mass reported as DCIS.

Pathology: IDC NOS, Grade: 1, LVI: Negative, Tumor size: 3mm, ER: 30%, PR: 10%, HER2: Triple positive, Ki67: 40%, SLNB: 0/5, Margins: Free.

Question:

Is she candidate for adjuvant therapy?

Recommended plan:

- Chemotherapy is recommended (Taxol and Herceptin).

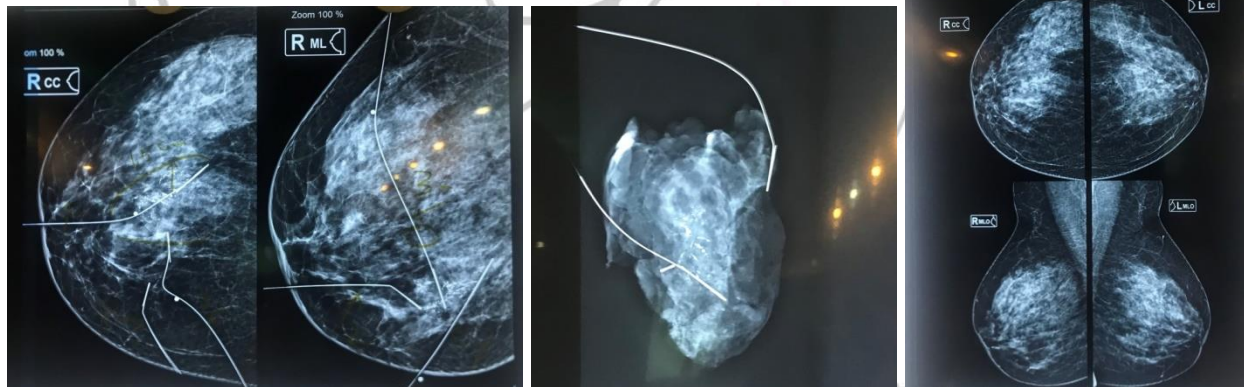


Figure 1, 2 & 3: Mammography shows Breast mass.