

Date: 14.10.2023; 1402/07/22

Patient's Name: S.I

Responsible Physician: Dr.Esphandbod

Patient presentation: A 34 year-old woman known case of locally advanced breast cancer of her left breast.

CNB: Triple Negative, Ki67: 30%.

PET scan: Left Lung upper lobe 10mm adjacent to Aorta, other Nodes in both Lungs.

Question:

Is it metastatic Breast cancer or oligo-metastasis?
What is the treatment plan?

Recommended plan:

- After chemotherapy completed, restage with PET CT scan, or CT scan with and without contrast and then will decide.

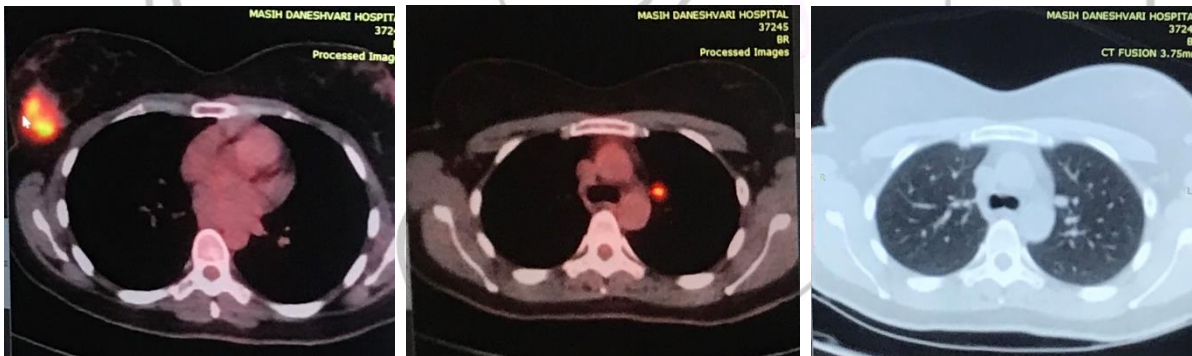


Figure1, 2 &3: Para-tracheal lymph nodes in PET scan and CT scan.