

Date: 29.07.2023; 1402/05/07

Patient's Name: M.H

Responsible Physician: Dr.Gomar

Patient presentation: A 53 year-old woman with history of right Breast cancer. She underwent BCS, SLNB, Chemotherapy and Radiotherapy (Tumor size: 25mm, ER: negative, PR: negative, HER-2: positive, Ki67:50%) in 1397.

Now she has local recurrence in her right breast. She underwent Mastectomy and Chemotherapy (stopped because of pulmonary thromboembolism).

Pathology: IDC, Tumor size: 40mm, ER: negative, PR: negative, HER-2: positive, Ki67: 10%.

Bone Scan: negative

Lung CT scan: in favor of COVID scar.

Question:

Should Irradiation be done or not?

Recommended plan:

- Irradiation is not recommended.

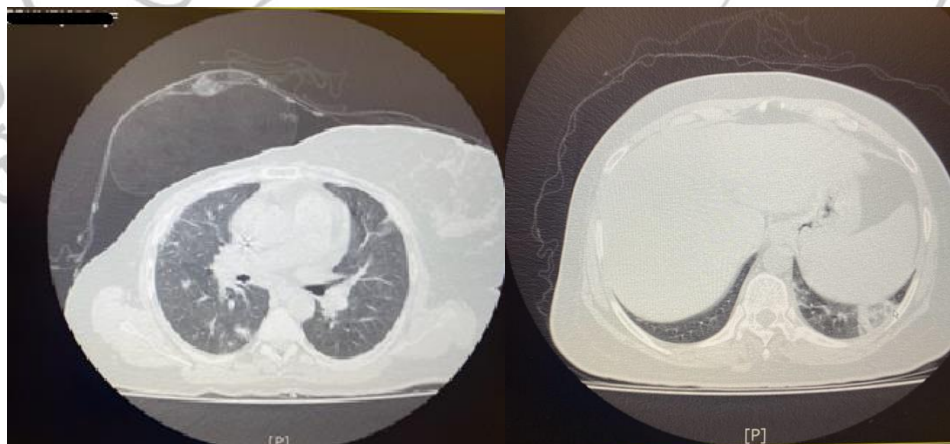


Figure 1, 2: Lung CT scan shows COVID19 scar