

Date: 15.07.2023; 1402/04/24

Patient's Name: O.I

Responsible Physician: Dr.Omranipour

Patient presentation: A 34 year-old woman known case of Breast cancer during Breast feeding.

Sonography:

Left: Edema, 40mm mass, suspicious ALN.

Right: Non mass enhancement, Skin thickening, 7 suspicious ALNs.

CNB: Left Sclerosing Adenosis, Microinvasion, ER: positive, PR: positive, HER-2: double positive, Ki67:3%.

Question:

What is the treatment plan?

Recommended plan:

- 1- Bilateral Breast CNB
- 2- Bilateral ALN FNA

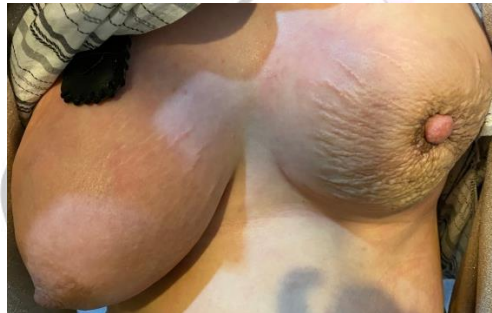

Figure1: Bilateral breast cancer

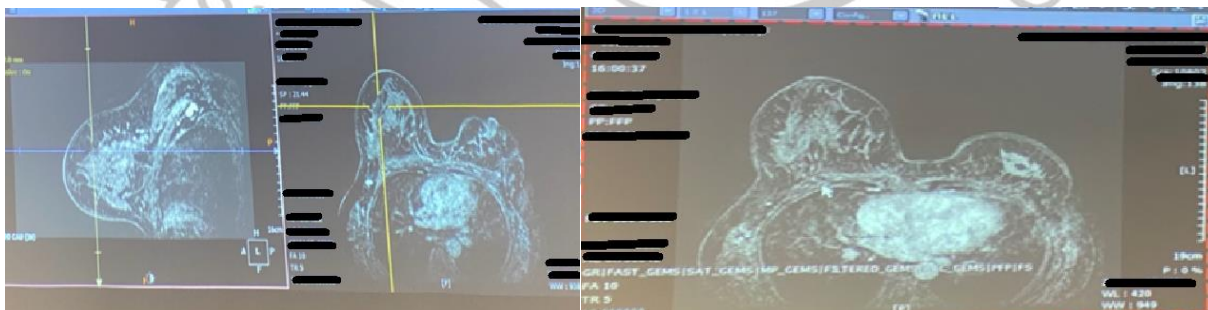


Figure 2, 3: MRI shows non mass enhancement suspicious for malignancy