

Date: 01.07.2023; 1402/04/10

Patient's Name: P.G

Responsible Physician: Dr.Tavakol

Patient presentation: A 36 year-old woman had right Breast mass one year ago (Tumor, Triple Negative, and ALN: positive). She underwent BCS, ALND (Complete response in breast, Lymph node: 1/13 is positive) and Radiotherapy. She has pelvic pain since her surgery.

Bone scan:

1st: Negative

2nd: Suspicious for left Iliac Metastasis

MRI: Suspicious for Pelvic Metastasis.

Question:

What is the treatment plan?

Recommended plan:

- Follow up with Bone scan.

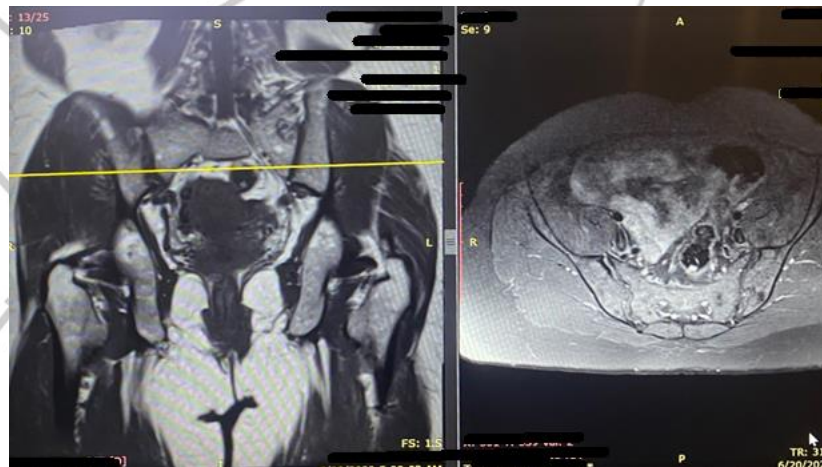


Figure1: Pelvic MRI shows no metastatic Lesions