

Date: 01.07.2023; 1402/04/10

Patient's Name: F.G

Responsible Physician: Dr.Jalaeefar

Patient presentation: A 49 year-old woman with left IDC 12 years ago. She underwent BCS and ALND (8/10+), Chemotherapy, Radiotherapy, 5 years of Tamoxifen and 5 years of Letrozole.

Now she has left Upper extremity Atrophy and left cervical mass (CNB: non diagnostic)

MRI: Increase thickness of left Brachial roots.

Question:

What is the treatment plan?

Recommended plan:

Excisional biopsy of Cervical mass.

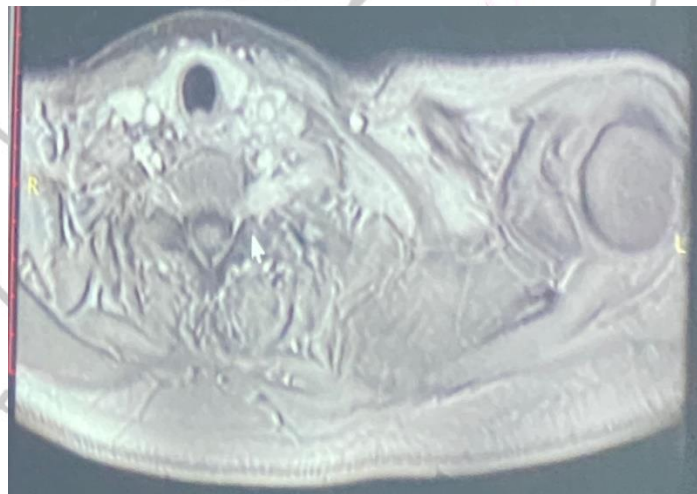


Figure 1 , Brachial root thickness in MRI