

**Date:** 10.16.2021; 1400.07.24

**Patient's Name:** R.A

**Responsible Physician:** Dr.Alipour

**Patient presentation:** A 56 year-old woman

Sonography: mass + cyst

US guided biopsy: papillary lesion

Lesion excised: DCIS reported

Pathology reviewed: one focus of ADH & intraductal papillomatosis, LIN 1, LIN 2

MRI: post-operative changes

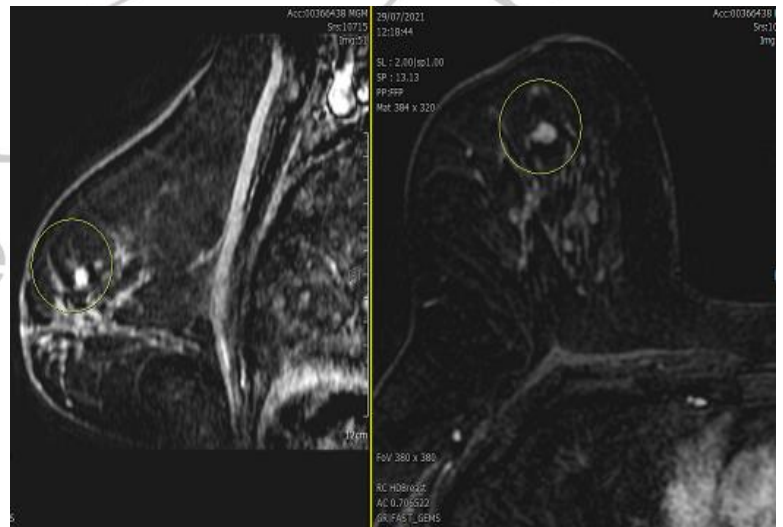
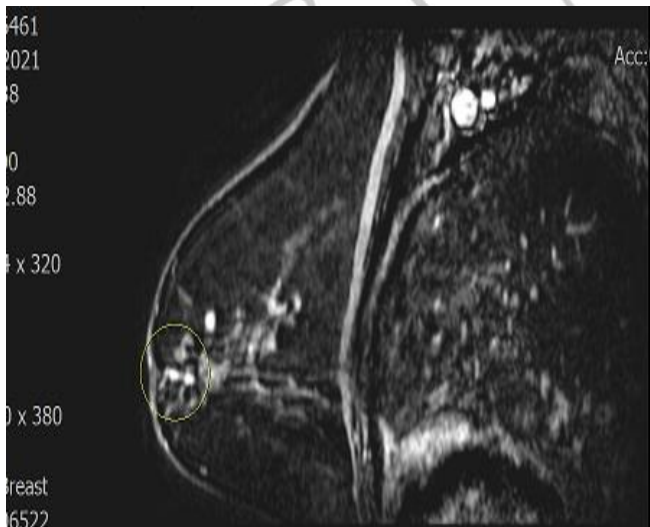
Target sonography & biopsy were done: papilloma & low grade DCIS & foci of LCIS

**Question:**

What is the next plan?

**Recommendation:**

BCS



مرکز تحقیقات بیماریهای پستان



Breast Disease Research Center