

Date: 17.4.2021;1400.1.28

Patient's Name: N.D

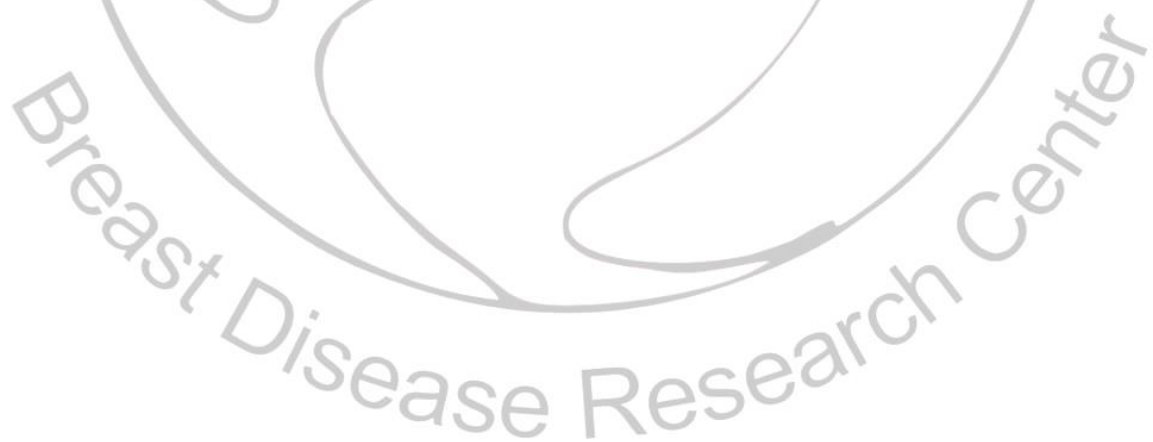Responsible Physician: Dr.Omranipour

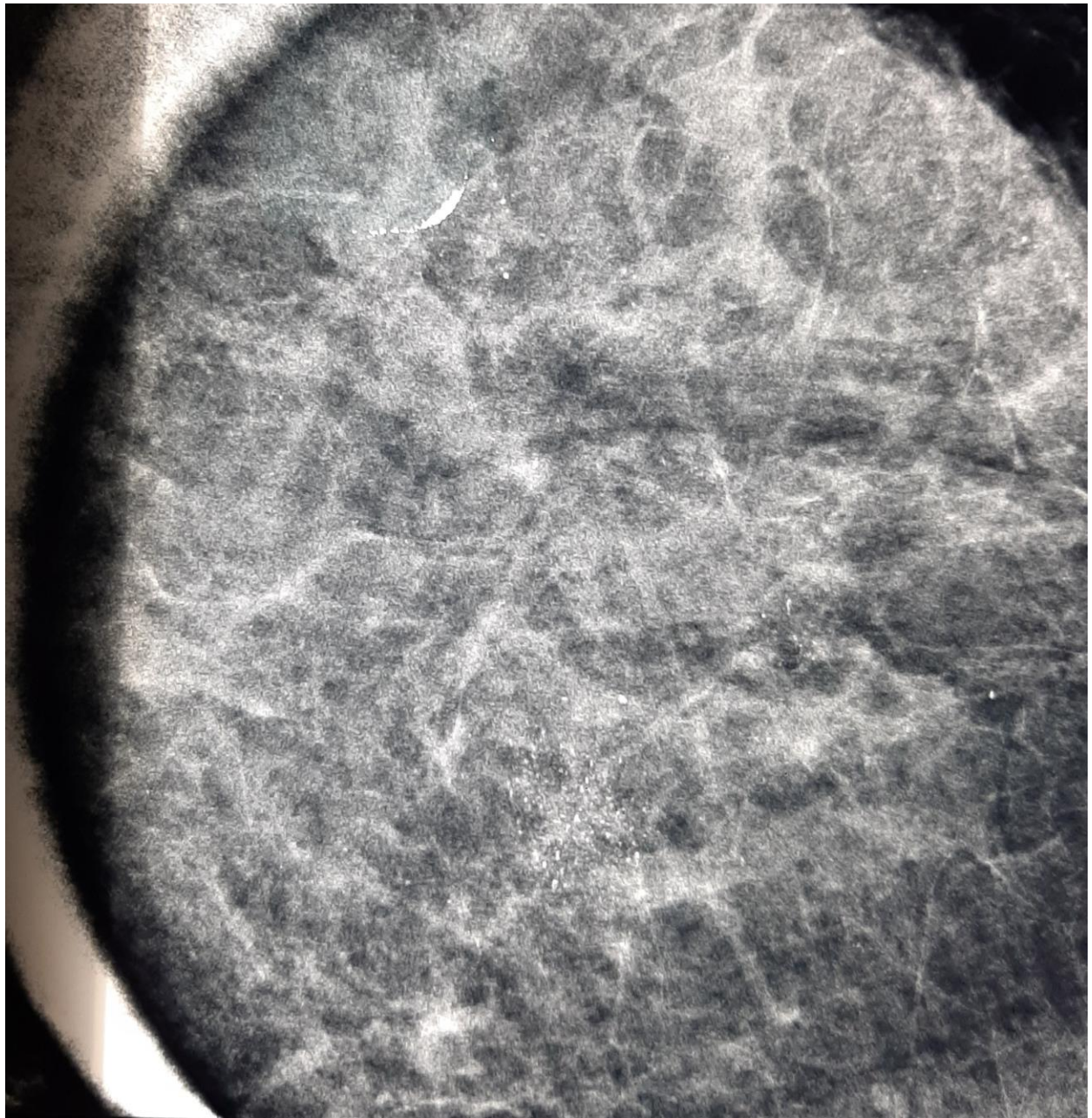
Patient presentation: A 45 year-old woman with right UOQ microcalcification who underwent VABx
VABx: LCIS and SA

Question: What's the next plan?

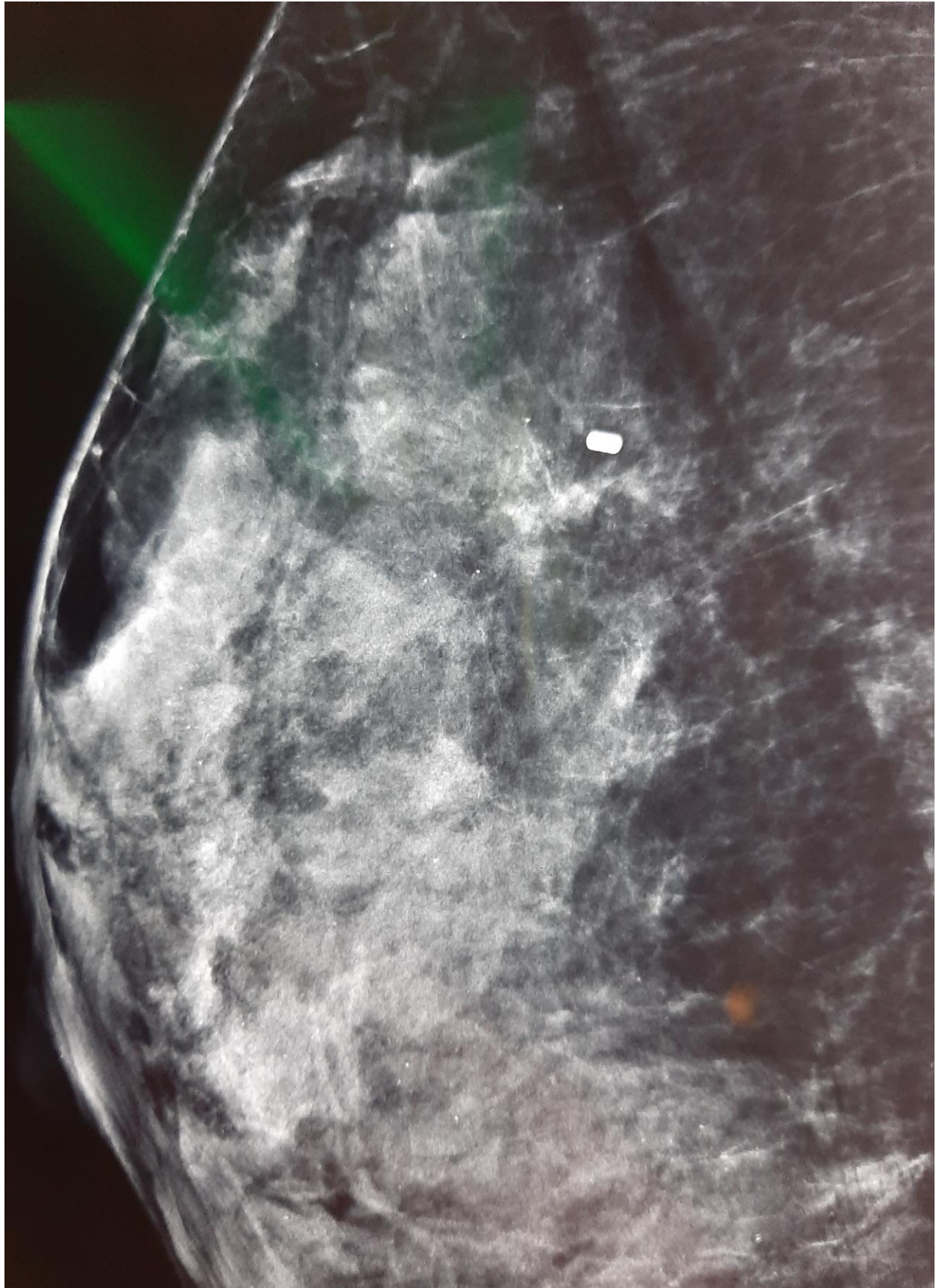
Recommendation:

- 1 .FCMV of right UOQ
- 2 .Breast MRI
- 3 .Wire guided excisional Bx.






East Disease Research C



مرکز تحقیقات بیماریهای پستان



Breast Disease Research Center