

Date: 15.05.2021; 1400.02.25

Patient's Name: M.H

Responsible Physician: Dr. Mohammadi

Patient presentation: A 53 year-old woman, known case of left breast cancer who under went with right breast cancer & past history of left breast cancer 5 years ago, Tamoxifen

FH: positive (both her sisters)

US: about 6 cm mass in UOQ and involved axillary LN

CNB: IDC, G2, ER+ (70%), PR-, HER2-,Ki67 20%, involved LN

CT scan: 4,5,5 mm nodules in lungs, 7 mm nodule in thyroid, T8-9 lytic lesions

WBS: wide spread bone metastasis

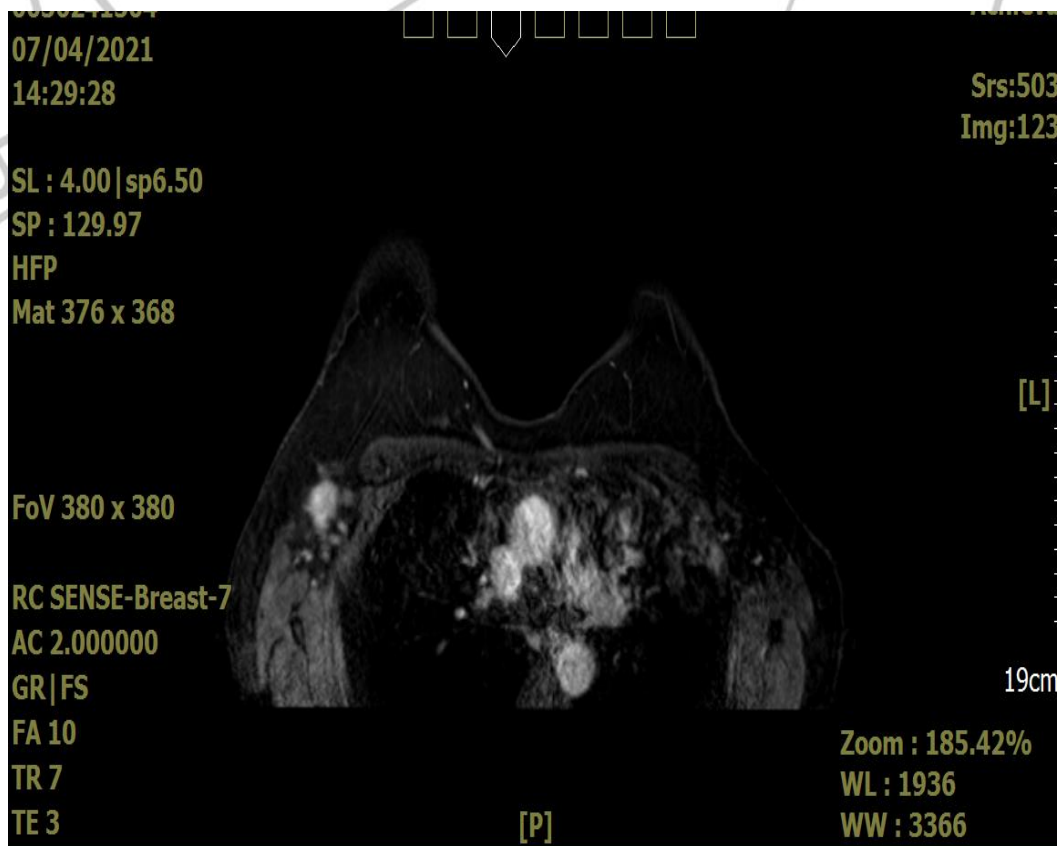
MRI: T5.8.9.10.11.12 and L1.3.5. iliac bone

Question:

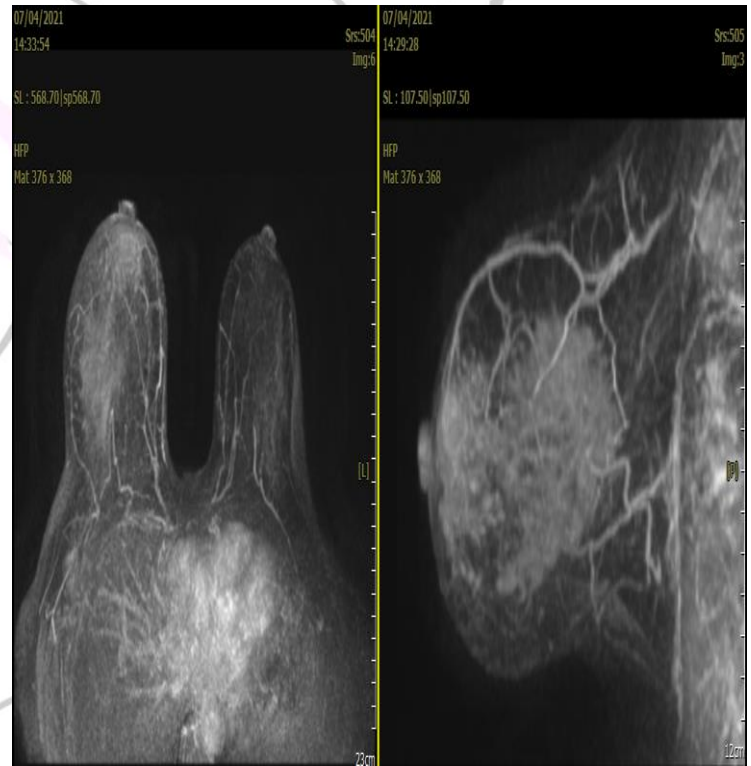
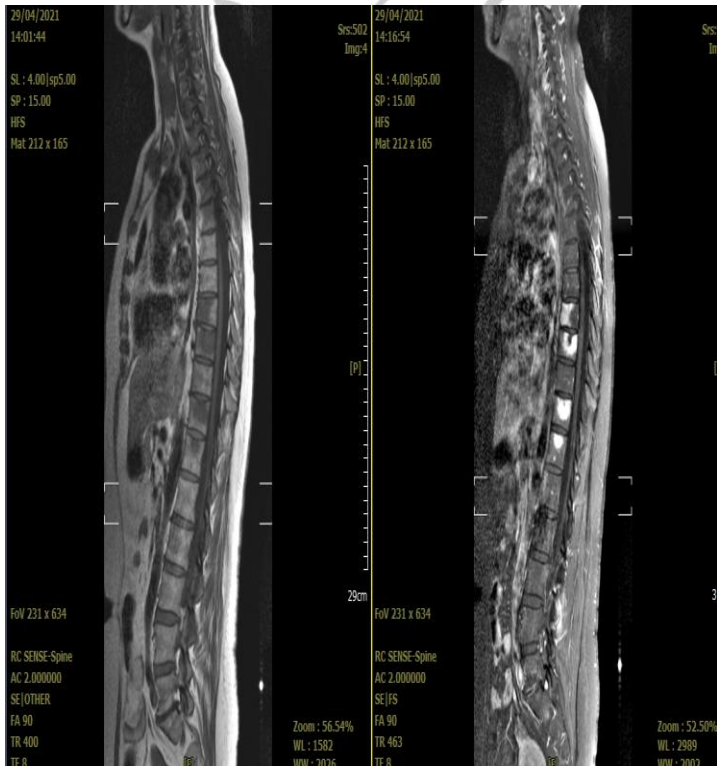
Is surgery helpful?

Recommendation:

1.Systemic CHT and bone RT and then re evaluation.



مركز تحقيقات بيماريهاي پستان



Breast Disease Research Center