

**Date:** 08.05.2021;1400.02.18

**Patient's Name:** S.L

**Responsible Physician:** Dr.Omranipour

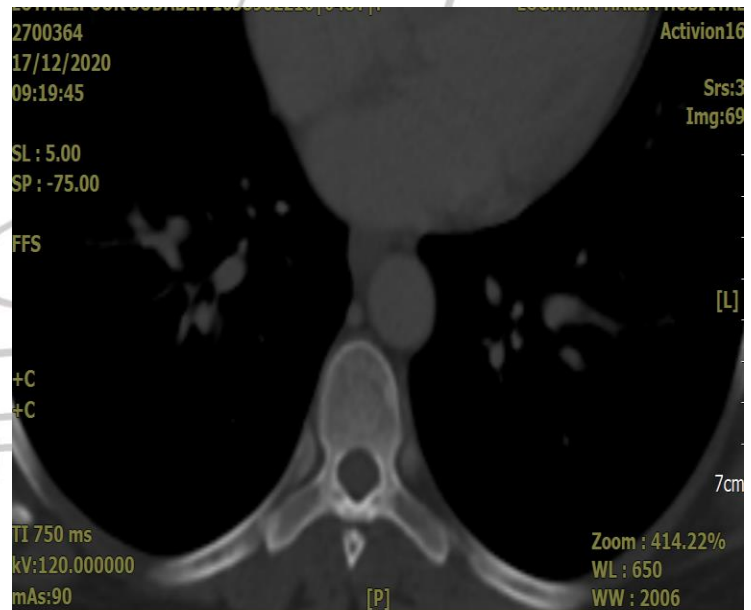
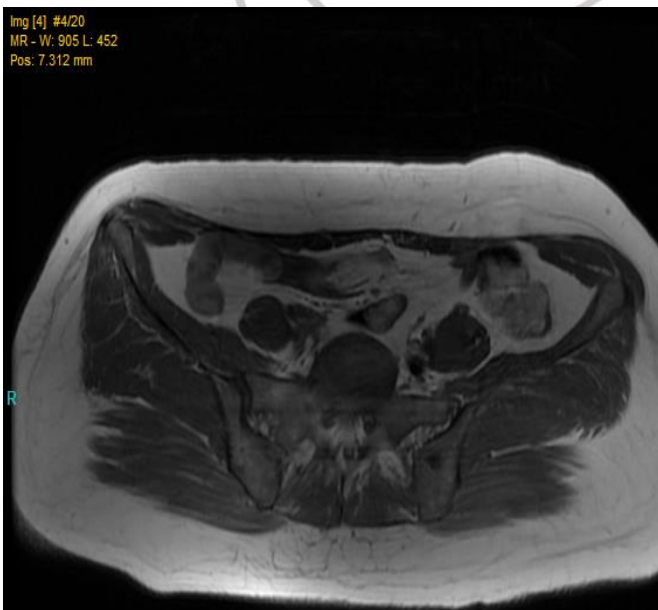**Patient presentation:** A 48 year- old woman with right breast cancer and oligo bone metastasis who underwent Neoadjvant chemotherapy then BCS and SLNBx and Limited AD(at least 5 LN).

Surgical Pathology: IDC, T= 3.6cm and 3cm,G1, LVI-, DCIS+ free margins(tumor bed received to margins), ER+, PR+, HER2 -, Ki67 30%, 3/3 LN+  
Frozen: 0/1 LN

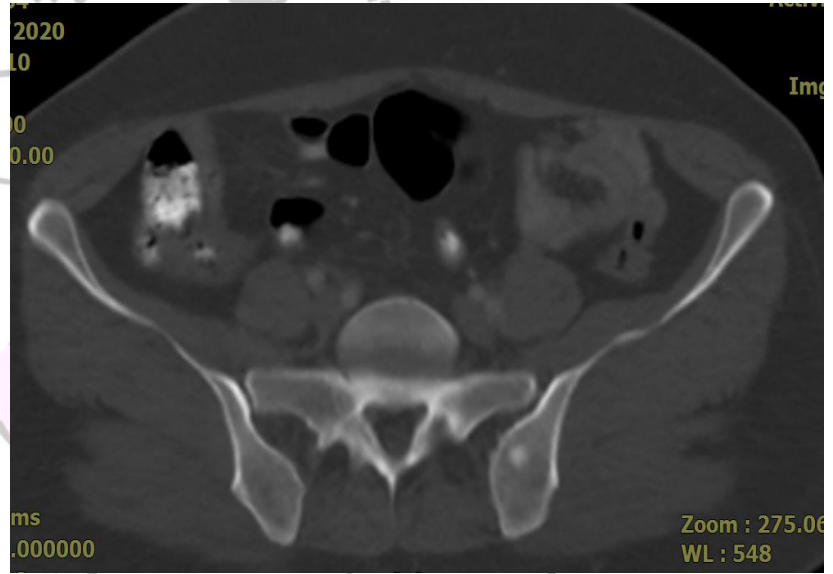
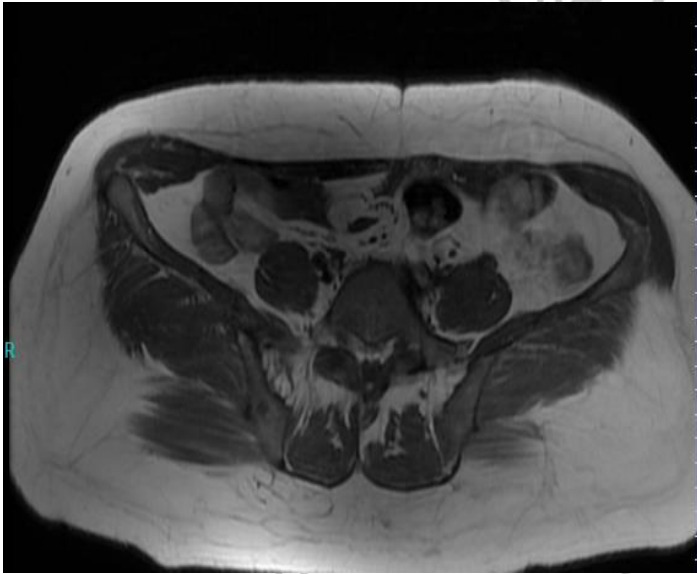
Bone scan: Left iliac body & T7-8 Lesions

**Question:** What's the next plan?

**Recommendation:** 1.chest & Abdominopelvic CT  
2.Spinal MRI.  
3.if CT & MRI are Normal, Axillary Dissection is recommended.



بیماریات



Breast Disease Research Center